

Original article:

Stylalgia: cure by a simple therapeutic maneuver

Maity. K¹, Sen . S², Mishra. S.³

¹ R.M.O cum Clinical Tutor , Dept. of E.N.T and Head-Neck surgery, I.P.G.M.E&R Kolkata. India.

² Assistant Professor, Dept of Anatomy, K.P.C Medical College, Kolkata,. India.

³ E.N.T Specialists in Private Practice, Kolkata, India.

Corresponding author: Dr. Sushmita Sen.

Abstract:

Aim : Our aim was to evaluate digital fracture of enlarged styloid as a clinical therapeutic manoeuvre , in office setting, in relieving symptoms of stylalgia , to avoid surgery or long term medications in stylalgia cases and to reduce O.P.D workload , investigations & reduce the cost of treatment.

Methodology: The study was conducted from June 2008 to April 2015. During this study period, total 71 numbers of patients presenting randomly to our outpatient department (OPD) were included. Therapeutic fracture of enlarged styloids done in O.P.D and cases were observed for a period ranging from minimum 1 month to maximum 5 yrs.

Results: Initially we had 82 cases of stylalgia, among them 11 had enlarged styloids so thick or so flexible that therapeutic fracture couldn't be done, those were taken for other modality like surgery or long term medication. Among those 11 cases 7 were males. Male styloids were found to be more tough. In rest 71 cases, actually in whom styloid fracture could be done , male were 13 (18.3%) and female were 58(81.7%). In 53 cases(64.6%) styloids were enlarged bilaterally . among them 20(24.4%) were having bilateral symptoms.

We achieved success rate within range 56.3% to 70.4%. Those got either complete or considerable improvement. 30% patients needed either surgery or long term medical therapy. Overall success rate in males were 38.5% and 77.6% in females.

Conclusion: with this simple O.P.D manoeuvre we could avoid surgery and long term medication in majority of cases of stylalgia.

INTRODUCTION:

The term 'Stylalgia' was coined by Watt W. Eagle in 1937⁽⁵⁾. Symptoms may include facial pain, ear pain, dysphagia, voice change and globus sensation that may cause frequent swallowing. These occur secondary to elongation of styloid process producing compression and irritation of adjacent structures. All these commonly called as ' Eagle's syndrome'. It is a rare disease and mostly remains underdiagnosed⁵. Most of the authors have seen and treated few cases each²⁻⁴. The styloid process is found to be enlarged in 4% of population¹⁰ (normal length being 25-30 mm)^{6-9,17}. But not all cases of enlarged styloid present with stylalgia.

The diagnosis of stylalgia is clinical.^{2,3,5} In a patient of suspected stylalgia, the clinical diagnosis is certain, if the enlarged styloid process is palpated through the tonsillar fossa¹¹. Pain and symptoms can be reproduced with pressure over the enlarged styloid. Different treatment options have been described conventionally for symptomatic patients. Initially conservative treatment options are tried conventionally which includes different analgesics, steroids either single or in combinations, antiepileptics like carbamazepine, amitriptyllin, gabapentin etc. in long terms in varying dosage . Some have tried local steroid injections with or without local anaesthetic with varying results.^{13,14,16} Surgery is planned in patients who do not respond to the medical line of management. Elongated styloid process can be excised, but some do not agree for excision of styloid process^[13,14,16]. Excision

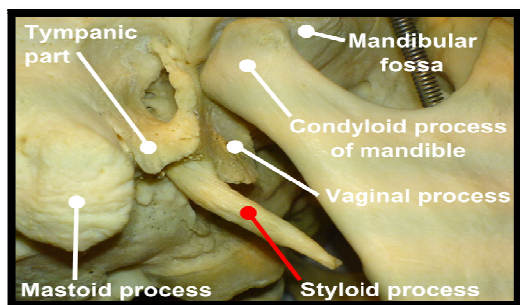
of styloid process can be done by trans-oral approach or external approach. In present days, the styloid process is also resected endoscopically through transoral route¹⁵.

We accidentally fractured the styloid process of one lady suffering from stylalgia, whose slender styloid process got fractured during the process of routine palpation and her symptoms improved dramatically. This encouraged us to conduct this study in hospital OPD.

Symptomatic patients with enlarged and palpable styloid process were included. Most of the patients earlier were not diagnosed properly and were treated as cases of chronic pharyngitis, globus pharyngitis, etc. And few were taking long term medicines for stylalgia .

As the diagnosis of Eagle's syndrome is clinical^{3,11} and the diagnosis can be confirmed by reproducing symptoms on palpation of enlarged styloid, we did not do any extra investigation for confirmation. The E.N.T OPD of SSKM hospital Kolkata is overburdened with average 500 or more patients everyday, for this reason, and as in case of Benign Paroxysmal Positional Vertigo ,where the diagnosis, treatment, manoeuvre, etc all are done in clinical OPD setting, we planned the study fully in office setting. We did not make any laboratory investigation mandatory.

ANATOMICAL CONSIDERATIONS:¹⁷



The styloid process is embryologically derived from the Richert's Cartilage i.e the skeletal derivative of second branchial arch. It extends dorsally upto the cartilaginous ear capsule. The dorsal part of the cartilage is ossified to form the stapes of middle ear. The succeeding part forms the styloid process of the temporal bone and the stylo-hyoid ligament where the cartilage cells disappear.

The styloid process is slender and pointed, and projects antero-inferiorly from the inferior aspect of the temporal bone. Length varies from few millimetres to an average 2.5 cm. Often it is almost straight, it can show a curvature, antero-medial concavity is most common.

The proximal or tympanohyal part is ensheathed by tympanic plate and the muscles and ligaments are attached to it's distal part (stylohyal).

The styloid process is covered laterally by the parotid gland, facial nerve crosses it's base, the external carotid artery crosses it's tip and medially the process is separated from the beginning of internal jugular vein by the attachment of stylopharyngeus muscle. Elongated styloid process can be caused by congenital elongation of styloid process due to the persistence of cartilaginous analogue of the styloid and can also be due to calcification of stylohyoid ligament by unknown mechanism and growth of osseous tissue at the insertion of stylohyoid ligament. Glossopharyngeal nerve, vagus and 3rd branch of trigeminal nerve and chorda tympani can be stimulated by the elongated styloid process and induce pain, swallowing difficulty, vague throat sensation,headachae, dysphagia etc.

METHODS:

This study followed the Declaration of Helsinki on medical protocol and ethics and the Regional Ethical Review Board of SSKM Hospital, Kolkata approved the study. We screened patients with symptoms of Eagle's syndrome. Most of them were being treated with medicines for chronic pharyngitis, globus pharyngitis, vague earache, and facial pain for variable duration without any long term benefits. Those patients having symptoms of more than 6 months duration were included. We palpated their tonsillar fossae bimanually in sitting position for styloid process. Those with enlarged and palpable styloid of the same involved side with reproduction of pain upon pressure were diagnosed as stylalgia as a clinical diagnosis. We divided styloid enlargement into three grading clinically:

Grade 1- when the tip of styloid is felt at the upper pole of tonsillar fossae.

Grade 2- when the tip of styloid reaches around the middle of tonsillar fossa.

Grade 3- when the tip of styloid reaches the lower pole and into the base of tongue.

Then, in the same sitting position we started our manoeuvre. This is a bimanual procedure with one hand giving support to the head and neck from outside covering the area of auricle, angle of mandible, mastoid and upper neck, and the index finger of the other hand is placed on the tonsillar fossa of the involved side against the external support. The styloid was palpated as high as possible from its tip and the index finger was fixed there. At this point the styloid can be best palpated and fixed at different head positions, from slightly flexed to slightly extended depending upon the medial and antero-inferior angulation of the styloid- which can vary from patient to patient and can be judged clinically by palpating in different positions. Also, the neck should be bended slightly laterally to the same side resting on the external hand. In this position, with the head fixed and index finger on styloid, moderate pressure was applied to the styloid with index finger. The direction of application of force was upwards posteriorly and laterally, with an effort to fracture the styloid process.

If the styloid gets fractured, a click can be felt and resistance is lost. Once failed, the manoeuvre was repeated 2-3 times with little gap of time to let the patient relax. In some cases, the styloid was thick and stout or so much flexible enough to resist fracture with moderate pressure. In those patients, the procedure was abandoned and the case was selected for other modalities of treatment like long term medicines or surgery.

In some non-cooperative and apprehensive patients, surface anaesthesia with 10% lignocaine can be used but we did not use it strategically as it masks pharyngeal symptoms and a false sense of wellbeing may be produced. It also makes the pharyngeal mucosa dry and makes swallowing difficult.

Patients were asked to take rest and were observed half an hour after successful manoeuvre. If patients complained of increased pain, they were given analgesics for 5-7 days; others were given analgesics as and when required basis. Patients were followed up for a variable period extending from minimum 1 month to maximum 5 yrs.

The study was conducted from June 2008 to April 2015. During this study period, initially total 82 numbers of patients presenting randomly to our outpatient department (OPD) were included in our study but later 11 (7 male & 4 female) cases were excluded as their styloids were either so thick or so malleable to resist manual fracture and the therapeutic manoeuvre was not applicable to them. In these cases patients were suggested of surgery or long term medical treatment. So, ultimately 71 patients entered the study. 13 were male and 58 female. Their

symptomatically enlarged styloid were fractured by the said manoeuvre and were followed up for a considerable period of time. The longest follow up period was 5yrs, shortest being 1 month.

After a follow up period of six months, those with persistent symptoms or relapse cases were taken for surgery or long term medical therapy after counselling.

RESULTS:

To start with we had 82 patients with symptomatic stylalgia having symptoms for more than 6 months .Among them 20(24.4%) were male and rest were female(75.6%).Therapeutic fracture of styloid was not possible in 11 cases, among them 7 were male and rest being females. We found in them, male styloid is thicker and stouter and in females the styloids were so flexible to resist fracture. 71 cases, actually in whom styloid fracture could be done , male were 13 (18.3%) and female were 58(81.7%).

TABLE-I Age Distribution

Age Group	Numbers
30-39 yrs	10
40-49 yrs	36
50-59 yrs	23
60-69 yrs	9
70-79 yrs	4
Total	82

In 53 cases(64.6%) styloids were enlarged bilaterally . among them 20(24.4%) were having bilateral symptoms.

TABLE-II Grade of Enlargement

Grade	Numbers	Percentage
Grade I	22	26.8
Grade II	52	63.4
Grade III	8	9.75
Total	82	100

So at the end of maximum 5yrs follow –up period 28 were symptom free (39.5%). 12 (17%) were feeling considerable improvement to the extent not requiring surgery or any long term therapy. 21 cases in total(29.5%) needed either surgery or long term therapy during therapy during follow-up period among them 13 being females and rest 8 were males. 10 patients dropped out of the follow-up schedule after a variable period, but they were either symptom free or having considerable improvement when last seen during follow-up.

Table-III Follow up chart

TIME OF FOLLOW UP	SYMPTOM FREE	CONSIDERABLE IMPROVEMENT	NO IMPROVEMENT	TOTAL
1 HOUR	10	34	27	71
2 WEEKS	46	15	10	71
1 MONTH	49	13	9	71
6 MONTHS	47	14	7	68
1 YEAR	42	16	2	60
2 YEARS	36	15	5	56
3 YEARS	33	15	2	50
4 YEARS	30	16	1	47
5 YEARS	28	12	4	44

DISCUSSION:

Normal length of styloid process is 25 to 30mm^{1,2,5,7} but the range can be from 1.5 to 4.77 cm⁷. Incidence of elongation of styloid or ossification of stylohyoid ligament is variable mostly in range of 4 to 7% among general population^{1,6,8}. Incidence can be as high as 30%. In this study we found most of our patients are within 40 to 59 years age group , total 59 pts (72%). Verma et al¹ found 72% of their cases. Almost every study found this, to be a problem of persons mostly in 4th decade or older and females are affected mostly , in a range within 65 to 85%. Here in this study we also see that female comprised 75.6% of total patients.

64.6% of our patients had bilateral enlarged styloids, among them 20 patients (24.4%) had bilateral symptoms. So its very clear that not every enlarged styloid is symptomatic. Verma et al¹ found 67% cases having bilateral styloid enlargement. He also reported a very useful method of reporting styloid enlargement, grade I,II,III, depending upon its enlargement into the tonsillar fossae and base of the tongue. We also adopted this system and found that most of our patients were having grade II enlargement (63.4%). He also reported this to be 54% in his case.

From the very beginning we considered this method of clinical therapeutic fracture of enlarged and symptomatic styloid as an in office manoeuvre, like ‘Epley’s’ done in BPPV cases. For this we didn’t make any laboratory investigations mandatory. We diagnosed stylalgia clinically as done in other studies also¹¹. We did the in office or in OPD therapeutic manoeuvre in an effort for symptom relief and to avoid surgery and long term recurrent medications and thereby reducing the burden on health system and cost f treatment.

Almost every study states, with conservative medication for a variable period, considerable nos. of patients can improve^{3,6,9,11,13,16}, failing which surgery can be considered, and surgery is mostly considered as the best management.^{3-6, 9, 11} analgesics, steroids, antidepressants, neuroleptics, anti psychotics , anti histamines, anti epileptics, muscle relaxants etc. ^{3,16} are used either in solo or in varying combinations for a considerable period of varying length as chronic therapy. The main drawbacks of conservative therapy are , it has to be used for a considerable long duration and symptoms usually recurred mostly after a variable period of withdrawal³.

Surgery can be done via conventional or endoscopic trans- tonsillar¹⁵ or via external approach. But trans-tonsillar approach is preferred by most authors because of less morbidity, technical ease and lesser complications.

In our study most of our patients were symptomatic for a variable duration ranging from 6 months to 10 yrs. Most of them were treated as chronic tonsillo-pharyngitis, GERD, vague throat discomfort etc. Initially we had 82 pts to start with stylalgia, among them 11 cases were having symptomatic elongated styloids but that couldn't be fractured with the said manoeuvre as they were either so thick or so malleable to resist therapeutic clinical fracture. Among them 7 were males and rest were females. We found male styloids were thicker and tougher. We could fracture therapeutically in 71 cases in O.P.D and observed them for one hour for any adverse effects, and we found no other than moderate pain in any of our patients. We followed our pts up after 2 wk, one month, 6 months, one year, and after then every yearly till 5 yrs in most cases maximally. We grouped our patients according to symptoms relief, into 3 groups during follow up. Those with complete relief being symptom free, we considered 'considerable improvement' as per patients feeling of gross relief of symptoms up to their satisfaction. The last group consist of patients feeling no improvement.

We found peak improvement in symptoms during the one month to one year period. After that few cases relapsed with symptoms. Those with mild symptoms, we followed them up but those with relapse as severe as the pre manoeuvre stage, were taken for other modes of therapy like surgery or long term medication after proper counselling. We planned a window period of six months after manoeuvre, after which this decision were taken (considering other mode of treatment).

We lost total 10 patients during follow up as they couldn't turn up after a variable period. This is a very common scene in countries like ours specially when they got relief of their symptoms, some of them don't come for follow-up due to different socio-economic factors and among them, most are females as in our case female drop out was 80%. At the point of dropout all of them were either symptom-free or having considerable improvement.

So, if we take this into account, we can say, from our results, we can avoid surgery or long term medications in 50 out of 71 patients i.e (70.4%), those become either symptom-free or had considerable improvement not needing surgery or any long term medical therapy. Even if we deduct 10 pts (those dropped out of follow up schedule) we have 56.3% success after five yrs follow up. So with this therapeutic manoeuvre we can achieve success in range of 56.3% to 70.4%. 21 out of 71 (29.6%) patients needed either surgery or long term medical therapy. Overall success rate in males 38.5% and in females 77.6%.

Even after few years, since we initiated this study, even after an exhaustive search, we didn't find any study regarding in office therapeutic fracture of styloid as a treatment in symptomatic stylalgia. Rather most studies points as surgical excision or shortening of styloid as definitive and best treatment^{9,11}.one study reports spontaneous fracture of enlarged styloid relieved symptoms¹² which supports our results. Albinas Gervicks et al³ had 31% cases who required surgery with 86.6% success. S.P.Yadav et al⁹ used dilatation and curettage method for styloidectomy through trans-tonsillar route. 40 operated, 31 (77.5%) symptom free, 5 (12.5%) had considerable improvement, 4 (10%) no improvement. We have seen in our study that with this simple therapeutic manoeuvre we can give results almost equivalent to surgery which is very much acceptable comparing data of other studies.

CONCLUSION:

This simple but effective O.P.D manoeuvre can give adequate symptom relief in cases of stylalgia .With this simple but effective in office therapeutic manoeuvre we were able to avoid long term medications and surgeries in vast majority of cases, thereby avoiding many investigations and repeated O.P.D visits for the patients of stylalgia, making already over burden O.P.D and O.T available to other patients. By doing this we can curtail the cost and burden on health care system for these chronic patients. At the end we feel again the need of larger and multi-centric trials on this.

REFERENCES:

1. Ravider Verma: Stylalgia. Indian journal of Otolaryngology- Head & neck surgery 1996; 48(4): 19-26.
2. Eagle WW. The symptoms, diagnosis, and treatment of elongated styloid process. Am J Surgery 1962; 28: 1-5.
3. Albinas Garvickas, Ricardas Kubilius, Gintautas Sabalys. Clinic, Diagnostics and Treatment Peculiarities of Eagle's Syndrome. Baltic Dental and Maxillofacial Journal 2004;6:11-13.
4. Prasad KC, Kamath MP, Reddy KJ, Raju K, Agarwal S. Elongated styloid process (Eagle's syndrome): a clinical study. J Oral Maxillofacial Surg 2002; 60(2):171-5.
5. Eagle WW. Elongated styloid process: report of two cases. Arch Otolaryngol 1937 ; 25: 584-587.
6. Eagle WW. Symptomatic elongated styloid process; report of two cases of styloid process-carotid artery syndrome with operation. Arch Otolaryngol 1949;49 : 490-503.
7. Mortellaro C, Biancucci P, Picciolo G, Vercellino V. Eagle's syndrome: Importance of a corrected diagnosis and adequate surgical treatment. J Craniofac Surg 2002; 13(6) : 755-8.
8. Harma R Stylalgia. Clinical experiences of 52 cases. Acta Otolaryngol 1966; 149:1224.
9. Yadav SP, Chanda R, Gera A, Yadav RK. Stylalgia- an Indian perspective. Otolaryngol 2001; 304-6.
10. Keur JJ, Campbell JPS, McCarthy JF, Ralph WJ. The clinical significance of the elongated styloid process. Oral Surgery, Oral Medicine, Oral Pathology 1986;61(4):399-404.
11. Murthy PSN, Hazarika P, Mary Mathai, Asha Kumar, Kamath MP. Elongated styloid process : an overview. International Journal of Oral and Maxillofacial Surgery 1990;19(4): 230-231.
12. Kaur A, Singh A, Singhal R, and Gupta R, ' this way, Self inflicted fracture of styloid process cures stylalgia'. J. Med Life. 2013 June 15; 6(2): 202-204.
13. Evans JT, Clairmont AA, 'The nonsurgical treatment of Eagle's syndrome'. Ear Nose Throat, 1976; 55: 94-95.
14. Steinman EP, 'Styloid syndrome in absence of an elongated process'. Acta Otolaryngology. 1968; 66: 347-356.
15. Matsamoto F, Kase K, 'Endoscopy assisted transoral resection of styloid process in Eagle's syndrome'. Head and Face medicine.2012; 8:21
16. Chandra A, Sharma A, Yatish SK, Kapoor R, Wahal AK, ' Stylalgia- our experience of conservative management'.American Journal of Advances in Medical Science. Jan 2014. (www.arnaca.com) pages 38-41.
17. Standring S, ed. Gray's Anatomy. The Anatomical Basis of Clinical Practice. 40th Edition. Churchill-Livingstone Elsevier. Edenberg. 2008.